

No Effects of In Vivo Micro-CT Radiation on Structural Parameters and Bone Marrow Cells in Proximal Tibia of Wistar Rats Detected after Eight Weekly Scans

Julienne E.M. Brouwers, Bert van Rietbergen, Rik Huiskes

Eindhoven University of Technology, W-hoog 4.128, P.O. Box 513, 5600 MB Eindhoven, The Netherlands

Received 21 September 2006; accepted 2 April 2007

Published online 13 June 2007 in Wiley InterScience (www.interscience.wiley.com). DOI 10.1002/jor.20439

ABSTRACT: Recently developed in vivo animal high-resolution micro-CT scanners offer the possibility to monitor longitudinal changes in bone microstructure of small rodents, but may impose high radiation doses that could damage bone tissue. The goal of this study was to determine the effects on the bone of 8 weeks of in vivo scanning of the proximal tibia in female Wistar rats. Eight weekly CT scans were made of the right proximal tibia of nine female, 30-week-old, retired-breeder, Wistar rats. Two weeks after the last weekly scan, a final scan was made. The left leg was only scanned during first and final measurements and served as a control. A two-way ANOVA with repeated measures was performed on the first and last measurements of left and right tibiae for six bone structural parameters. Bone marrow cells were flushed out and tested for cell viability. No significant difference was found between left and right for any of the bone structural parameters ($p > 0.05$). Structure model index and trabecular separation significantly changed as a result of aging, while none of the other parameters did. No significant difference was found between left and right in absolute and percentage number of cell viability. We did not find any indication that the applied scanning regime, in combination with the particular settings used, would affect the results of in vivo bone structural measurements in long-term studies using aged, female Wistar rats. However, careful consideration should be made when determining the number of scans, particularly when a different experimental design is used. © 2007 Orthopaedic Research Society. Published by Wiley Periodicals, Inc. *J Orthop Res* 25:1325–1332, 2007

Keywords: rodent animal model; radiology; aging; osteoporosis

INTRODUCTION

Recently developed animal high-resolution in vivo micro-CT scanners offer the possibility to monitor longitudinal changes in bone microstructure of small rodents.^{1,2} These scanners, combined with image registration software, provide a promising technique^{1–4} to obtain information regarding changes in bone microstructure due to metabolic diseases, such as osteoporosis; metastatic conditions, such as bone metastases; and bone adaptation resulting from mechanical stimuli. These in vivo scanners, however, impose a relatively high ionizing radiation dose, the actual value of which depends on scanning frequency and image resolution.

In longitudinal studies, the cumulative radiation dose can be on the order of a few gray (Gy), a

level at which tissue damage may occur.¹ Bone marrow is rather sensitive to radiation: in humans, whole-body dosages starting at about 250 mGy lead to reduced lymphocyte counts.⁵ A single dose of 5 Gy led to significant changes in bone regeneration, while a 2.5-Gy dose did not.⁶ A 2-Gy dose resulted in alternative growth-plate structures.⁷ Doses of 400 mGy and lower showed no effects on osteoblast differentiation and activity in vitro.⁸ Bone marrow contains osteogenic progenitor cells that are closely related to bone formation. Damage to bone marrow cells could cause changes in bone formation rate and thereby alter bone structure.

Presently, it is unknown if tissue damage will affect results of longitudinal in vivo micro-CT studies. In most studies investigating the effects of radiation in animal bone, the whole animal was exposed, which is not representative for in vivo micro-CT scanning, where typically only a small part of the leg is irradiated. In a recent study performed to address this issue, ovariectomy (OVX) treated mice were used, and no effects of radiation were observed.⁹ In another study, however, in

Correspondence to: Bert van Rietbergen (Telephone: 0031-40-247-4773; Fax: 0031-40-244-7355; E-mail: b.v.rietbergen@tue.nl)

© 2007 Orthopaedic Research Society. Published by Wiley Periodicals, Inc.

which three weekly *in vivo* scans were made of the proximal tibia in three different mouse strains, significant differences were found between the structural bone parameters of the scanned and the control leg for the final measurements of two strains.¹⁰ These results suggest that the effects of radiation dose on bone structure may depend on experimental design. Additionally, it is unknown if the results obtained for mice are representative for rats. The goal of this study was to determine whether an intensive 8-week *in vivo* scanning regime of the rat proximal tibia leads to changes in bone structural parameters and in bone marrow cell viability.

MATERIALS AND METHODS

Nine female, 30-week-old, retired-breeder, Wistar rats were obtained from Harlan (Horst, The Netherlands) and allowed to acclimatize for 7 days before the start of the experiment. The animals were housed at 22°C, exposed to a 12:12-h light-dark cycle, and allowed to eat and drink *ad libitum* from a standard laboratory diet. The experiment was approved by the Animals Ethics Committee of the University of Maastricht, The Netherlands.

Weekly *in vivo* CT-scans (Scanco vivaCT 40 scanner, Scanco Medical AG, Bassersdorf, Switzerland) of the right proximal tibia were made during 7 weeks at an isotropic resolution of 15 μm (Fig. 1). Two weeks after the last scan, a final scan was made, since radiation damage was shown to be maximal after that period.^{11,12} During scanning, the animals were anesthetized with isoflurane for 75 min. With the settings chosen, a single scan (70 kV, 85 μA , 1,000 projections per 180 degrees, 350 ms integration time), consisting of a stack of 212 images, covers only 3.18 mm axially of the tibia. To include the




Figure 1. Rat lying in the *in vivo* micro CT-scanner with one leg fixated in the developed leg-fixating device.

whole proximal region, two adjacent scans were required, resulting in a total scanning time of about 35 min. In the beginning of the experiment, some CT-scans showed movement artifacts due to poor leg fixation. As a result of these artifacts, the two adjacent stacks did not align properly. We decided to generate two separate stacks of 3.18 mm of the proximal tibia, overlapping 0.3 mm. These stacks were later attached by in-house registration software,¹³ resulting in a CT-scan that covered 6.06 mm. A new leg-fixating device was later developed that solved the movement artifact problem, but the procedure with overlapping stacks was maintained.

To determine the radiation dose, the local CT dose index (CTDI) was measured for the scanning protocol to which the animals were subjected using a dose meter with ionization chamber (Solidose 400, RTI, Mölndal, Sweden). Two different measurements were performed. The first measurement was made in air and resulted in a CTDI value of 939 mGy. The second measurement was made at the center of a 35-mm perspex cylinder that was used as a phantom and resulted in a total dose of 441 mGy. Since soft tissues are surrounding the bone when scanning *in vivo*, the value to which the actual bone is exposed is lower than the value measured in air, although it will be higher than the value measured in the perspex cylinder, which is much larger than soft tissue around the tibia. CTDI measure takes the actual dose profile into account and results in a value that can be considerably higher than the local dose values measured and thus represents a higher estimate. Although two partly overlapping image stacks were made, the dose in the overlapping region will not be higher than elsewhere. This is due to the fact that the dose profile of the cone beam is such that the dose is maximal at its center and decreases considerably near the sides of the scanned region. Since, by definition, the overlapping areas are the edges of two scanned regions, the lower radiation dose compensated for the double exposure. Naturally, the whole-body dose increases when imaging multiple stacks. However, since only a small part of the animal was radiated, the whole-body dose was very small in all cases.

The left tibia, serving as a control, was only scanned at the first and the final time points and underwent a SHAM-scan for all other measurements. During the SHAM measurements, the animals were put in the micro-CT scanner with their left legs placed in the holder for the same time period as required for a normal measurement, but the legs were not exposed to any radiation. This was done to rule out other possible harmful effects of the procedure, such as stretching of the leg. The design of the rat holder was such that the left leg was not exposed to radiation while scanning the right leg.

Image processing included Gaussian filtering and segmentation. The same filter and segment values were used for every measurement of every animal ($\sigma = 0.7$, support = 1, threshold density = 0.504 g HA/cc). From every baseline and follow-up CT-scan, the metaphyseal area was manually selected by drawing a

contour file by the same operator. For each measurement, a new contour file needed to be drawn, because the rats still showed minor growth and remodeling and therefore the previous contour file would not exactly fit. The images were rotated such that each slice showed the bone longitudinally, and therefore the whole region below the growth plate could be selected. From the selected region, bone structural parameters were automatically determined: bone volume fraction (BV/TV), connectivity density (Conn.D), structure model index (SMI), and trabecular number, thickness, and separation (Tb.N, Tb.Th, and Tb.Sp, respectively). In addition, the average attenuation coefficient of the trabecular bone tissue was determined for all measurements to determine if any changes in bone mineral content could be detected. We focused on the metaphyseal bone, since this part contains newly formed bone from the growth plate, and the growth plate is known to be the most sensitive to radiation. We presumed that if no effects in the metaphysis were found, none would be present in the epiphysis.

The reproducibility of the measurements was investigated in an adjoining pilot study in which the right tibia of a dead rat was measured four times on the same day using the same protocol as used in the radiation effects study. After each measurement, the animal was removed from the holder and repositioned. A contour file was made for the first scan and was applied to the follow-up scans after image registration. Bone structural parameters were determined for all CT-scans according to the method described earlier. Based on these results, the coefficient of variation (CV) was calculated for each parameter. The CV was less than 1% for all parameters (BV/TV, SMI, Tb.Th, Tb.Sp, Tb.N) with the exception of Conn.D, for which the CV was 2%.

When two CT-scans of the same animal are made at different time points, the position of the animal in the scanner will not be exactly the same and therefore the CT-scans will also differ in position. To detect bone structural changes on a micro-level, one CT-scan needs to be translated and rotated to match the other. We developed image registration software that registers two scans based on minimizing the correlation coefficient.¹³ Every weekly scan was registered with the first scan, thereby revealing any possible changes in microstructure.

It was assumed that any natural changes in the bone structural parameters, throughout the experiment, would be similar in the left and right legs. Furthermore, it was assumed that the effects of the radiation dose on the structural parameters would be negligible if no significant differences in structural parameters after 9 weeks were observed between left and right. Any damaging effect of the first scan on the left tibia was assumed to have been resolved after 9 weeks. A two-way ANOVA with repeated measures was performed on the first and last measurement of the left and the right tibia to determine time effects, group differences, and time*group effects. This was done for all structural parameters and the average attenuation coefficient of the trabecular

bone tissue. In addition, a regression analysis was performed for the structural parameters of all measurements from the right legs of all rats. For all statistical tests, *p*-values below 0.05 were considered significant.

The animals were sacrificed after their last scan. To determine cell radiation damage, the scanned parts of both left and right tibiae were sawed off, using an Accutom5 precision cut-off machine (Struers GmbH, Maassluis, The Netherlands). A needle filled with α -medium, containing several antibiotics, was placed in the scanned part of both tibiae and released under pressure, flushing out the bone marrow cells. The cell suspensions were incubated at 37°C during 1–6 h for storage, after which a cell viability test was performed with trypan blue. No influence of storage time was seen. The absolute number and the percentage of living and dead cells were determined for both tibiae. A paired Student's *t*-test was performed to determine any significant difference in absolute and percentage numbers of viable cells between the left and right tibia.

RESULTS

All animals showed normal body weight gains. No loss of hair and no skin erosions occurred throughout the experiment, indicating healthy conditions. Figure 2 shows the same slice taken from two registered, processed CT-scans of the same rat at weeks 0 and 9. After image registration, minimal linear growth had occurred, which can be expected in 30-week-old rats.¹⁴

With the initial rat holder, movement artifacts were occasionally present in the scans, due to poor leg fixation. Since these artifacts resulted in errors in the determination of bone parameters, they were excluded from further analysis. The criterion for exclusion was based on the blurring of the image and on the correlation coefficient generated by the registration procedure when fitting the overlapping region, as observed by the operator; this resulted in the exclusion of eight measurements.



Figure 2. Left: longitudinal section through CT-scan showing bone at week 0 and 9 of same rat after global registration. Yellow indicates bone at week 0, green indicates bone at week 9, black is overlap. Note that linear growth has taken place, shown by the slight downward movement of the metaphyseal trabeculae. Also, the shape of the bone has slightly changed due to bone remodeling. Middle: longitudinal section showing a typical CT-scan after registration of the two stacks, black is the overlap. Right: Zoomed section of CT-scan showing overlap of two stacks after registration.

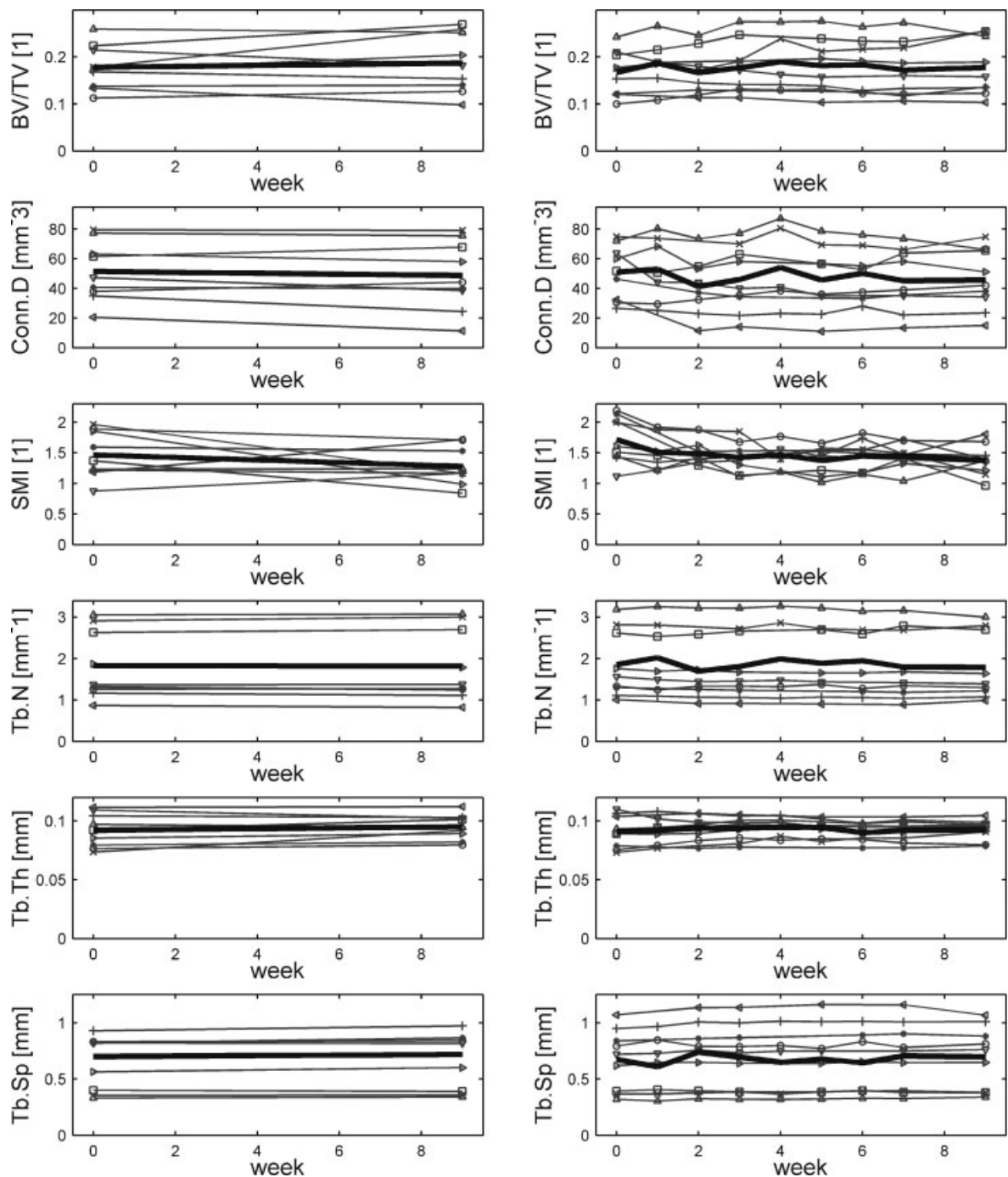


Figure 3. Morphological parameters for all animals individually for the left, control tibia (left column) and right, scanned tibia (right column). The same marker is used for every animal in each figure. The thick black line indicates the average value per measurement.

Measurements showing only minor movement artifacts were included for analysis, but may have slightly affected the bone parameter values and thus the precision. Figure 3 shows the bone structural parameters for all rats longitudinally, where the missing markers indicate excluded measurements. Figure 4 shows mean and standard deviations for all structural parameters for the first

and last measurements of both left and right tibia. BV/TV and SMI were found to be significantly different at baseline between left and right.

A two-way ANOVA with repeated measures on the first and last measurements of both tibiae revealed no significant differences between left and right for any structural parameter. For SMI and Tb.Sp, significant time effects were determined

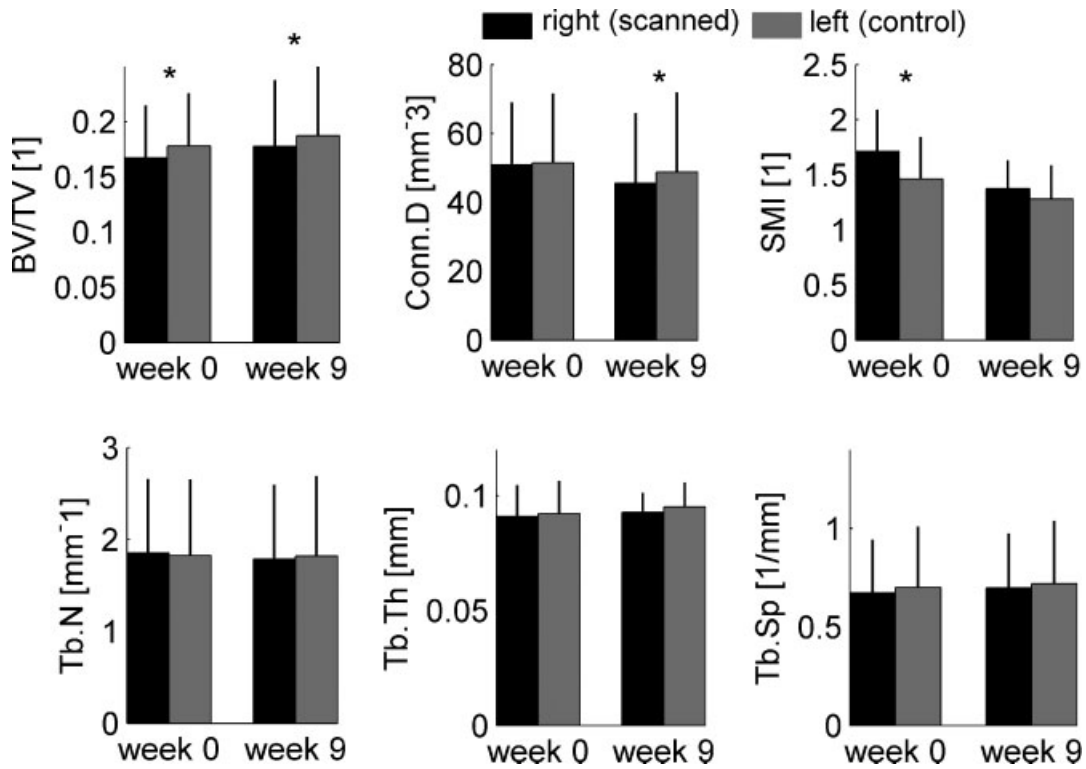


Figure 4. Average values and standard deviations for all structural parameters of the first and last measurements in right (scanned) and left (control) legs. Asterisk indicates a significant difference between left and right at that time-point.

(Table 1). SMI decreased in time and Tb.Sp increased in time. The two-way ANOVA with repeated measures showed no significant differences between left and right and no significant changes over time for the bone tissue attenuation coefficients ($p = 0.10$ and $p = 0.48$, respectively).

A regression analysis was performed on all measurements for the right tibia, for all structural parameters of each rat, to determine differences in response between rats. While on average a significant effect of age was found on Tb.Sp and SMI, the regression analyses for all rats individually on Tb.Sp showed significant increases for some, non-significant decreases for others and nonsignificant increases for yet others, indicating the diversity. A

similar diversity was seen for SMI, where some rats showed significant increases while others showed nonsignificant increases or decreases. Diversity was also seen for all other structural parameters; significant increases were found in some and nonsignificant increases or decreases in others.

In the trypan blue test, the percentage of dead cells were determined to be on average 6% and 7%, respectively, for the right (scanned) and left (control) leg. A paired Student's *t*-test revealed no significant difference between the percentage of living cells of right and left tibiae ($p = 0.39$). The absolute numbers of living and dead cells were also not significantly different ($p = 0.37$ and $p = 0.47$, respectively). Figure 5 is a typical image from

Table 1. Two-Way ANOVA with Repeated Measures: *p*- and *F*-values^a

Variable	BV/TV		Conn.D		SMI		Tb.N		Tb.Th		Tb.Sp	
	<i>F</i>	<i>p</i>	<i>F</i>	<i>p</i>	<i>F</i>	<i>p</i>	<i>F</i>	<i>p</i>	<i>F</i>	<i>p</i>	<i>F</i>	<i>p</i>
Time	2.17	0.162	1.16	0.299	10.1	0.007 ^a	3.63	0.077	1.31	0.269	14.6	0.002 ^a
Group	0.207	0.656	0.122	0.732	1.147	0.302	0.003	0.956	0.044	0.836	0.000	0.988
Time*group	0.004	0.952	0.137	0.717	0.171	0.685	3.038	0.103	0.122	0.732	0.762	0.398

BV/TV, bone volume fraction; Conn.D, connectivity density; SMI, structure model index; Tb.N, Tb.Th, Tb.Sp, trabecular number, thickness, and separation.
^aSignificant value.




Figure 5. A typical image from the trypan blue staining of tibial bone marrow cells. Arrow indicates a dead cell. Mostly living cells can be seen (white dots).

trypan blue staining of tibial bone marrow cells, showing mostly living cells.

DISCUSSION

In this study, we determined whether an intensive 8-week, *in vivo* scanning regime of the rat proximal tibia would lead to changes in bone structural parameters or bone marrow cell viability. The scanning frequency was higher than necessary for most studies, thus representing a worst-case scenario. Even then, we found no significant changes in bone structural parameters and in bone marrow cell viability as a result of radiation damage.

Our results agree with the work from Judex et al.,⁹ in which no radiation effects were found in OVX mice. They do, however, seem to contradict the results from a radiation study using a similar radiation dose from Klinck et al.,¹⁰ who reported a significant difference between the structural bone parameters of the scanned and control leg at the final measurement for two out of three strains of mice used. These mice, however, were between 8 and 10 weeks old and still had an active growth plate. Our results also do not correspond with observations from Waarsing et al.^{14,15} Additional dose measurements with the same dose meter using their micro-CT equipment and protocols, however, revealed that their applied CTDI, in air as well as in water, was twice as high as that in our study, which could explain why effects were seen in their studies and not in ours. In general, results from different studies may be difficult to compare, as some authors report the radiation dose measured in air while others report the dose

measured in water or in polymethyl methacrylate (PMMA). Our findings suggest, however, that the applied dose was close to the maximum acceptable dose and that its effects may depend on the type, age, and strain of animal, and on scanning parameters, scanning regime, and type of scanner.

Another explanation for differences between our and earlier studies would be the stretching and immobilization of the leg required to position it in the holder, which could affect the bone structure. During a scan, the radiation source must rotate around the object and, therefore, the leg must be pulled down away from the body and fixed in that position. Our fixation device was such that the hip and knee joint were maximally stretched and the ankle joint was kept in a 90° angle. Stretching could lead to a period of reduced loading of the bone for some period after the experiment, which could induce bone loss. Our study design, however, was such that the effect would be the same for left and right, and therefore we only determined the effect of the radiation, which was the goal of the study. In earlier studies that reported effects of radiation, however, no sham scans were made for the contralateral leg.

A significant decrease in SMI, which indicates a change from more rod-like to plate-like bone, and a significant increase in Tb.Sp were found in both tibiae with aging. Although Tb.Sp is expected to increase with age, SMI is not expected to decrease¹⁶; it might indicate that mostly rod-like trabeculae have disappeared. The fact that changes in SMI and Tb.Sp took place in both tibiae indicates that normal bone remodeling was taking place and that bone cell activity was not much affected by the radiation. This was supported by the fact that linear growth and bone remodeling were seen in the scans after global registration (Fig. 2). No significant overall effect of time was determined in the two-way ANOVA with repeated measures for BV/TV, Conn.D, Tb.Th, and Tb.N in the right leg. However, the regression analyses showed significant increases in some rats, significant decreases in others, and nonsignificant changes in yet others, indicating that the individual effects of time varied per rat to some extent.

Figure 3 shows considerable variability in the follow-up measurements. For each measurement, a new contour file needed to be drawn by the operator to select the region of interest (ROI), because the rats still showed minor growth and remodeling. The operator decided manually if newly formed bone was labeled as trabecular bone and included in the ROI. Between each measurement, there was also minor linear growth, which means in between

two measurements, newly formed bone entered the ROI and some bone exited the ROI on the distal side. Also, minor movement artifacts and experimental variation may have influenced variability.

Since the scanner was calibrated with a hydroxyapatite phantom, a direct, linear relationship existed between the bone tissue attenuation coefficient measured and the hydroxyapatite density. The attenuation coefficient did not change significantly over time and did not differ between left and right, indicating that the hydroxyapatite density did not change as a result of aging or radiation. The implications of these results remain limited due to partial volume effects in the scan. However, the results suggest that bone-tissue mineralization did not change as a result of radiation.

No significant difference was found between the percentage of viable cells in right and left tibiae, indicating neither long- nor short-term effects on cell viability, which concurs with expectations based on the CTDI.⁸ Overall effects on all cells were determined; certain cell types may have shown relatively large cell deaths. However, since the percentage of dead cells was very low, and our aim was to test the legitimacy of using this in vivo micro-CT scanning regime, we found it reasonable to determine the overall number of cells. Cell damage might occur after several hours, after which it would be repaired again. Such damage would have remained undetected by our methodology. However, our most relevant finding for future in vivo micro-CT experiments is that no long-term damage was found. The final scan was taken 2 weeks after the last weekly scan, so any possible undetected cell damage was at least resolved within 2 weeks.

The significant differences in BV/TV and SMI between left and right legs are probably due to natural variance. However, the region of interest selected from the image by the operator may also have been slightly different.

The rats used in this study were retired breeders. The variation of structural parameters within the group of rats was quite large (Figs. 3 and 4). BV/TV and Tb.Th were lower and Tb.Sp was higher than normally seen in 30-week-old Wistar rats,¹⁷ but these results are consistent with previous data on retired breeders.^{18,19} Although structural parameters may differ between normal rats and retired breeders, the rats used were considered suitable for determining any possible radiation damage in general for female Wistar rats.

Although the left leg was not exposed to radiation when scanning the right leg, systemic radiation effects could have occurred when scanning

the right leg, possibly affecting the left leg. However, since the scanned area is relatively small compared to the total body volume, we assumed that any systemic effect was negligible.

In this study, an in vivo rodent high-resolution micro-CT scanner was used, suitable to monitor changes in bone microstructure per animal individually, rather than by comparing averages of different groups. This reduces the number of animals needed per experiment by a factor as high as the number of measurements performed. Furthermore, each animal served as its own control, thereby enabling detection of subtle changes in bone structural parameters by paired and repeated measures statistics.

In conclusion, we did not find any indication that the scanning regime applied, in combination with the particular settings used, would affect the results of in vivo bone structural measurements in long-term studies using aged, female Wistar rats. However, careful consideration should be made when determining the number of scans and the CTDI, particularly when a different experimental design is used.

ACKNOWLEDGMENTS

This work was funded by The Netherlands Organization for Scientific Research.

REFERENCES

1. Waarsing JH, Day JS, van der Linden JC, et al. 2004. Detecting and tracking local changes in the tibiae of individual rats: a novel method to analyse longitudinal in vivo micro-CT data. *Bone* 34:163–169.
2. David V, Laroche N, Boudignon B, et al. 2003. Noninvasive in vivo monitoring of bone architecture alterations in hindlimb-unloaded female rats using novel three-dimensional microcomputed tomography. *J Bone Miner Res* 18:1622–1631.
3. Waarsing JH, Day JS, Weinans H. 2005. Longitudinal micro-CT scans to evaluate bone architecture. *J Musculoskelet Neuronal Interact* 5:310–312.
4. Waarsing JH, Day JS, Weinans H. 2004. An improved segmentation method for in vivo microCT imaging. *J Bone Miner Res* 19:1640–1650.
5. Bushberg JT, Seibert JA, Leidholdt EM, et al. 2005. *The essential physics of medical imaging*. Baltimore: Williams and Wilkins.
6. Jacobsson M, Jonsson A, Albrektsson T, et al. 1985. Alterations in bone regenerative capacity after low level gamma irradiation. A quantitative study. *Scand J Plast Reconstr Surg* 19:231–236.
7. Bisgard JD, Hunt HB. 1936. Influence of roentgen rays and radium on epiphyseal growth of long bones. *Radiology* 26: 56–68.

8. Dare A, Hachisu R, Yamaguchi A, et al. 1997. Effects of ionizing radiation on proliferation and differentiation of osteoblast-like cells. *J Dent Res* 76:658–664.
9. Judex S, Chung H, Torab A, et al. Micro-CT induced radiation does not exacerbate disuse related bone loss. In: Transactions of the 51st annual meeting of the ORS. Washington, DC, february 2005. Poster no 1546.
10. Klinck RJ, Boyd S. 2006. The effects of radiation on ovariectomized mice as a function of genetic strain by in vivo micro-computed tomography. In: Transactions of the 28th annual meeting of the ASBMR, Philadelphia, PA
11. Engstrom H, Jansson JO, Engstrom C. 1983. Effect of local irradiation on longitudinal bone growth in the rat. A tetracycline labelling investigation. *Acta Radiol Oncol* 22: 129–133.
12. Engstrom H. 1987. Effects of irradiation on growing bones. *Swed Dent J Suppl* 45:1–47.
13. Verhulp E, van Rietbergen B, Huiskes R. 2004. A three-dimensional digital image correlation technique for strain measurements in microstructures. *J Biomech* 37:1313–1320.
14. Waarsing JH, Day JS, Verhaar JA, et al. 2006. Bone loss dynamics result in trabecular alignment in aging and ovariectomized rats. *J Orthop Res* 24:926–935.
15. Waarsing JH. 2006. Exploring bone dynamics by in-vivo micro-CT imaging (dissertation). Erasmus Medical Center, Rotterdam, The Netherlands. This is a dissertation.
16. Boyd SK, Davison P, Muller R, et al. 2006. Monitoring individual morphological changes over time in ovariectomized rats by in vivo micro-computed tomography. *Bone* 39:854–862.
17. Iwamoto J, Takeda T, Ichimura S, et al. 2003. Comparative effects of orchidectomy and sciatic neurectomy on cortical and cancellous bone in young growing rats. *J Bone Miner Metab* 21:211–216.
18. Kimmel DB, Bozzato RP, Kronis KA, et al. 1993. The effect of recombinant human (1–84) or synthetic human (1–34) parathyroid hormone on the skeleton of adult osteopenic ovariectomized rats. *Endocrinology* 132:1577–1584.
19. Lane NE, Kumer JL, Majumdar S, et al. 2002. The effects of synthetic conjugated estrogens, a (cenestin) on trabecular bone structure and strength in the ovariectomized rat model. *Osteoporos Int* 13:816–823.